

Japanese adults is 0.14 to 0.18 sec, 0.42 sec is thought to be exceedingly rare in this population. Price (1968) suggested that a prolongation of the P-R interval, secondary R in lead V<sub>1</sub>, and a reduction in size with notching of S in V<sub>1</sub> were characteristic features of the electrocardiogram in 47,XYY males. The first two of these features were observed in the present case. There was no evidence of a cardiac abnormality to account for the electrocardiographic findings. More study is needed to clarify whether prolongation of the P-R interval in 47,XYY males is more than a coincidence.

SHINICHIRO NANKO<sup>1</sup> AND JUNICHI MIYAWAKI<sup>2</sup>  
*Institute of Brain Research<sup>1</sup> and Department of Gerontology,<sup>2</sup> University of Tokyo, School of Medicine, Hongo 7-3-1, Bunkyo-ku, Tokyo, Japan*

#### References

- Borgaonkar, D. S. (1972). The XYY chromosome male or syndrome. In *Progress in Medical Genetics*, Vol. 10, ed A. G. Steinberg and A. G. Bearn. Grune and Stratton, New York. Cited by Borgaonkar and Shah (1974).
- Char, F., and Borgaonkar, D. S. (1971). Electrocardiogram in males with the 47,XYY karyotype. *Lancet*, **1**, 1242.
- Nanko, S., Saito, S., and Makino, M. (1979). X and Y chromatin survey among 1581 Japanese juvenile delinquents. *Japanese Journal of Human Genetics*, **24**, 21-25.
- Noël, B., Quack, B., Durand, Y., and Rethoré, M. (1969). Les hommes 47,XYY. *Annales de Génétique*, **12**, 223-236.
- Price, W. H. (1968). The electrocardiogram in males with extra Y chromosomes. *Lancet*, **1**, 1106-1108.
- Price, W. H., Lauder, I. L., and Wilson, J. (1974). The electrocardiogram and sex chromosome aneuploidy. *Clinical Genetics*, **6**, 1-14.
- Price, W. H., and Wilson, J. (1971). Electrocardiographic studies in individuals with different sex chromosome complement. *Fourth International Congress of Human Genetics*, **233**, 531 (Abst.). Excerpta Medica, Amsterdam.
- Steiness, E., and Nielsen, J. (1970). The electrocardiogram in males with the 47,XYY karyotype. *Lancet*, **1**, 1402-1403.

Requests for reprints to Dr S. Nanko, Institute of Brain Research, University of Tokyo, School of Medicine, Hongo 7-3-1, Bunkyo-ku, Tokyo, Japan.

## A case of complete testicular feminisation and 47,XYY karyotype

**SUMMARY** A very rare case of complete testicular feminisation with a 47,XYY sex chromosome complement is described. The X-chromatin is positive. The subject studied, who belongs to a family in which four other members have Morris's syndrome and have a 46,XY karyotype, is a perfect phenotypic female. The endocrine situation is unique and resembles, in part, that of subjects with Klinefelter's syndrome.

While there are many published reports on complete testicular feminisation with a 46,XY karyotype, it is rare to find the same condition with a 47,XYY complement. The report of German and Vesell (1966) describes Morris's syndrome and a 47,XYY karyotype in monozygotic twins, and Bartsch-Sandhoff *et al.* (1976) reported a case of incomplete testicular feminisation with the same chromosome complement. Subjects with the same syndrome and mosaicism of the sex chromosomes are very rare (Uozumi *et al.*, 1967; Gordon *et al.*, 1969). We report the clinical, endocrine, and cytogenetic findings of a subject with a rare coexistence of Morris's syndrome and a 47,XYY karyotype.

#### Case report

The proband, 35 years old, the eighth of nine children, is one of five subjects with complete testicular feminisation in two successive generations of the same large family (Fig. 1). At the time of her birth her non-consanguineous parents were 40 years old (mother) and 48 years old (father). She is a phenotypic female with primary amenorrhoea, attractive, and married. At 14 years of age she was operated on for a right inguinal hernia, a frequent finding in this condition. Height (167 cm) and body proportions are normal and similar to those in other subjects with Morris's syndrome. Facial, pubic,

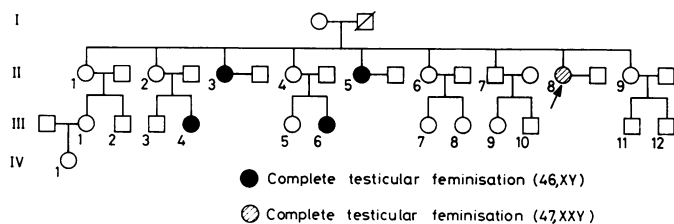


Fig. 1 Pedigree of family

and axillary hair is absent and the breasts are well developed with barely protruding nipples. The external female genitalia are perfectly normal and there is no hypertrophy of the clitoris that could suggest the incomplete form of the syndrome. No internal genitalia could be detected by palpation, other than a rounded form on the left side which is probably a gonad. The vagina is shorter than normal (approximately 3 cm) and terminates blindly.

#### LABORATORY EXAMINATIONS

Routine haematology and radiological examinations

were normal. Hormonal data were as follows: (a) urinary 17-ketosteroids, 42.7 mg/24 h; (b) 17 OH-CS, 2.8 mg/24 h; (c) radioimmunological sampling of the hypophyseal gonadotrophins, LH, >50 IU/24 h, FSH, >50 IU/24 h; (d) plasma testosterone, 1.15 ng/ml (3.99 nmol/l).

#### CYTOGENETIC STUDIES

Chromosomal analysis was carried out on mitoses obtained from a short-term culture of peripheral blood lymphocytes. The 47,XXY karyotype, present in all the numerous mitoses examined, was shown by

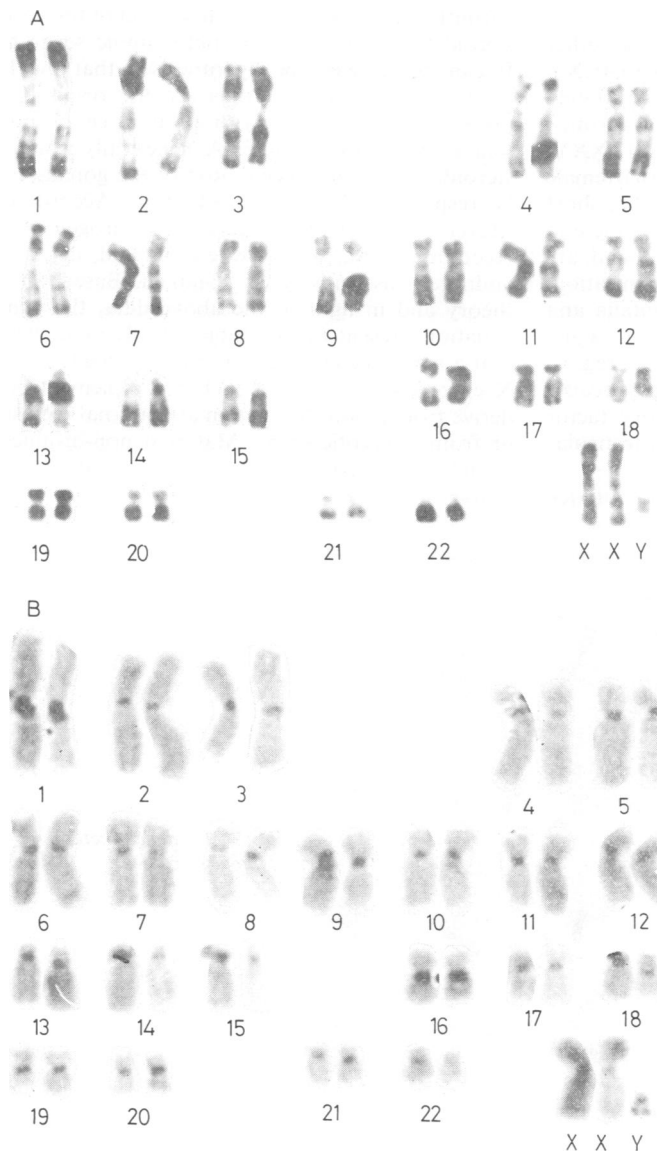


Fig. 2 (A) R-banded karyotype and (B) C-banded karyotype of the proband.

R-banding (Dutrillaux and Lejeune, 1971) and C-banding (Salamanca and Armendares, 1974) (Fig. 2). The only detail of relevance concerns the Y chromosome which was rather short in the heterochromatic portion. On the other hand, a Y chromosome with the same characteristics was present in the chromosome complement of the proband's brother, the only normal male of the second generation (Fig. 3). Bilateral buccal smears were X-chromatin positive.

### Discussion

Our proband is a member of a family in which other cases of complete testicular feminisation with 46,XY karyotype are present (Fig. 1). The subject studied has many characteristics of Morris's syndrome, although the chromosome complement is 47,XXY. In fact, primary amenorrhoea, normal external female genitalia, absence of internal female genitalia, short vagina which terminates blindly, lack of pubic and axillary hair, all elements present in the proband, are among the principal signs of testicular feminisation. In particular, the absence of internal genitalia and the presence of a blindly terminating short vagina seem to be an indirect demonstration that regression of the Müllerian ducts has taken place, because of the presence of the Müllerian-inhibitory factor secreted by the fetal gonad, probably of a testicular type.

The endocrine situation of the proband is unique

and is different from that typical of the syndrome, which is found in the other affected family members. The rather low levels of plasma testosterone (1.15 ng/ml, 3.99 nmol/l) are close to those in subjects with Klinefelter's syndrome. These values and increased gonadotrophin levels lead us to believe that, in our case also, the testes are represented by dysgenetic seminiferous tubules and by histologically and functionally abnormal Leydig cells. The high value of the 17-ketosteroids (42.7 mg/ml) cannot be attributed to either syndrome. The proband refused to allow a second blood sampling which would have permitted us to examine the dose-level of the various steroid fractions after chromatographic separation. It can nevertheless be hypothesised that the high levels of the 17-ketosteroids are the result of the presence of metabolites with an androgenic activity weaker than testosterone. A genetically abnormal steroidogenesis or degeneration of the gonads could be responsible for such a situation. According to Meyer *et al.* (1975), the gene for androgen cytosol receptor in man, which, when mutated, determines androgen insensitivity, is X-linked. Based on this theory and in light of the above data, the clinical situation present in our subject leads us to believe that a homozygous state has been reached. The two X chromosomes present in her complement could derive from a non-disjunction at maternal meiosis II or from a zygotic error. Maternal non-disjunction would also be consistent with a maternal age of 40 years.

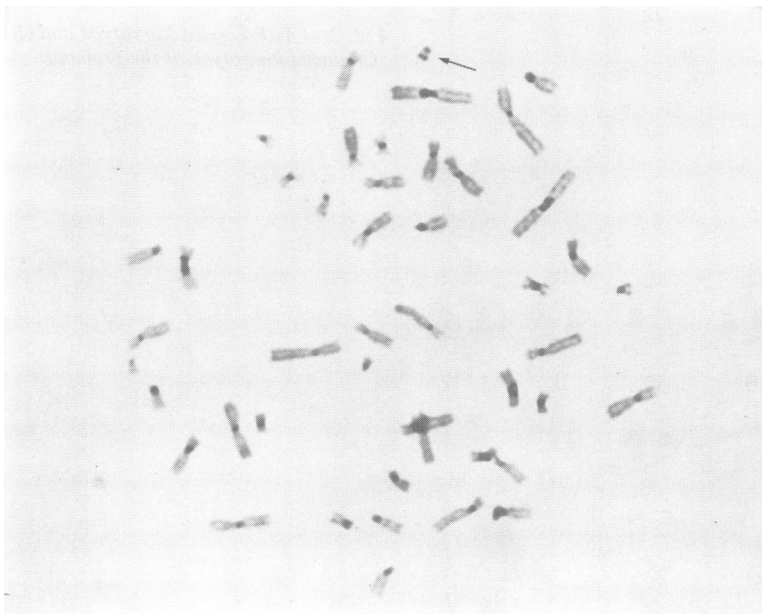

Fig. 3 C-banded metaphase of proband's brother.

The authors wish to thank G. Bettini, F. Pimpinelli, and C. Giannmartino for technical assistance.

M. GERLI,<sup>1</sup> G. MIGLIORINI,<sup>2</sup> V. BOCCHINI,<sup>2</sup>  
G. VENTI,<sup>2</sup> R. FERRARESE,<sup>1</sup> E. DONTI,<sup>2</sup> AND  
G. ROSI<sup>2</sup>

<sup>1</sup>*Clinica Ostetrica e Ginecologica, and*

<sup>2</sup>*Istituto di Biologia Generale, Università di Perugia, 06100 Perugia, Italy*

#### References

- Bartsch-Sandhoff, M., Stephan, L., Röhrborn, G., Pawlowitzki, I. H., and Scholz, W. (1976). Ein fall von testiculärer feminisierung mit dem Karyotyp 47,XXY. *Human Genetics*, **31**, 59–65.
- Dutrillaux, B., and Lejeune, J. (1971). Sur une nouvelle technique d'analyse du caryotype humain. *Comptes Rendus Hebdomadaires des Séances de l'Académie des Sciences*, **272**, 2638–2640.
- German, J., and Vesell, M. (1966). Testicular feminization in monozygotic twins with 47 chromosomes (XXY). *Annales de Génétique*, **9**, 5–8.
- Gordon, L. D., Krmpotic, E., Zelinger, B. B., and Rosenblum, L. E. (1969). Sex chromosome mosaicism in the testicular feminization syndrome. *Obstetrics and Gynecology*, **34**, 6, 779–782.
- Meyer, W. J., Migeon, B. R., and Migeon, C. J. (1975). Locus on human X chromosome for dihydrotestosterone receptor and androgen insensitivity. *Proceedings of the National Academy of Sciences of the USA*, **72**, 4, 1469–1472.
- Salamanca, F., and Armendares, S. (1974). C bands in human metaphase chromosome treated by barium hydroxide. *Annales de Génétique*, **17**, 135–136.
- Uozumi, T., Nozaki, R., Matsumoto, K., Seki, T., and Furujiama, Y. (1967). Endocrinological studies of a case of mosaicism (XO/XY/XXY) with clinical appearance of testicular feminization syndrome. *Acta Endocrinologica*, **54**, 193–207.

Requests for reprints to Dr Emilio Donti, Istituto di Biologia Generale, Università di Perugia, Via del Giochetto, 06100 Perugia, Italy.

## A further case of a new syndrome including midface retraction, hypertrichosis, and skeletal anomalies

**SUMMARY** The clinical and radiological features of a male child with multiple malformations are described. He appears to be an example of a new syndrome recently described by Schinzel and Giedion (1978).

We report a further case of a syndrome recently described by Schinzel and Giedion (1978) consisting of midface retraction, club feet, hypertrichosis,

hypoplasia of dermal ridges, and radiological skeletal abnormalities in skull, ribs, hands, and feet. Our case developed intractable epilepsy and spasticity and exhibited profound developmental and growth retardation, as did the surviving sib described in the earlier report.

#### Case report

This patient was born in January 1978, the result of the third pregnancy of healthy, non-consanguineous, 26-year-old parents. Previous pregnancies had resulted in a miscarriage at 3 months' gestation and the birth in 1975 of a female who, at the age of 3 years, is of normal appearance and development. The mother is now pregnant for the fourth time. In the pregnancy leading to the birth of our patient, amniocentesis was performed without complication at 16 weeks' gestation, the indication being maternal anxiety because a distant relative had Down's syndrome. A normal male fetal karyotype was reported. There is no other known family history of birth defect. There was no history of infection or exposure to drugs, and spontaneous vertex delivery of a male infant weighing 3.5 kg occurred at 41 weeks' gestation.

The infant was transferred after birth to the Special Care Baby Unit because of his unusual appearance. He was noted to have an odd face, hypospadias, and bilateral talipes equinovarus. The right kidney was palpably enlarged and a systolic murmur was heard.

Investigations including haemoglobin, blood urea and electrolytes, thyroid function tests, and urine amino-acid chromatography were within normal limits. Cytomegalovirus titre 1:20, rubella virus (HAI) 1:40 (CFT) 1:10, toxoplasma antibody 1:16. Chromosome analysis with Giemsa banding showed a normal male karyotype 46,XY.

The infant was snuffly and difficult to feed, and at 4 weeks of age began to have frequent fits which have not been controlled with phenobarbitone or sodium valproate. Detailed examination at the age of 10 weeks showed an infant with generalised hypertrichosis and upswept hair (Fig. 1 and 2). The skull was dolichocephalic with large anterior and posterior fontanelles and frontal bossing. There was a mongoloid slant of the palpebral fissures, proptosis, and the pupils, which were small, did not react to light. The nasal bridge was depressed and the nose upturned with multiple telangiectases over the nose and cheeks. The ears were low set, posteriorly rotated, and had protruding lobes. The foreskin was hooded with a ventrally placed meatus. The testes were in the scrotum. There was bilateral talipes equinovarus, dimples on both elbows and the right knee, and the nails were hyperconvex (Fig. 3). The kidneys were



## **A case of complete testicular feminisation and 47,XXY karyotype.**

M Gerli, G Migliorini, V Bocchini, et al.

*J Med Genet* 1979 16: 480-483

doi: 10.1136/jmg.16.6.480

---

Updated information and services can be found at:

<http://jmg.bmj.com/content/16/6/480>

---

### **References**

*These include:*

Article cited in:

<http://jmg.bmj.com/content/16/6/480#related-urls>

### **Email alerting service**

Receive free email alerts when new articles cite this article. Sign up in the box at the top right corner of the online article.

---

### **Notes**

---

To request permissions go to:

<http://group.bmj.com/group/rights-licensing/permissions>

To order reprints go to:

<http://journals.bmj.com/cgi/reprintform>

To subscribe to BMJ go to:

<http://group.bmj.com/subscribe/>